

PROCEEDINGS OF SPIE

SPIDigitalLibrary.org/conference-proceedings-of-spie

Infantile hemangiomas evaluation based on hyperspectral imaging

Valery Shupletsov, Ilya Gorunov, Maxim Sergienko, Ivan Zhurilo, Elena Potapova, et al.

Valery Shupletsov, Ilya Gorunov, Maxim Sergienko, Ivan Zhurilo, Elena Potapova, Viktor Dremin, "Infantile hemangiomas evaluation based on hyperspectral imaging," Proc. SPIE 12627, Translational Biophotonics: Diagnostics and Therapeutics III, 126272F (11 August 2023); doi: 10.1117/12.2670954

SPIE.

Event: European Conferences on Biomedical Optics, 2023, Munich, Germany

Infantile hemangiomas evaluation based on hyperspectral imaging

Valery Shupletsov^a, Ilya Gorunov^a, Maxim Sergienko^b, Ivan Zhurilo^c,
Elena Potapova^a, and Viktor Dremin^a

^aResearch & Development Center of Biomedical Photonics, Orel State University, Orel, Russia

^bScientific and Clinical Multidisciplinary Center for Medical Care for Mothers and Children
named after Z.I. Kruglaya, Orel, Russia

^cOrel Region Children's Polyclinic No.1, Orel, Russia

ABSTRACT

This study presents a hyperspectral optical imaging system for the diagnosis of infantile hemangiomas. Pilot studies were conducted in the clinic on infants. As the main results, the parameters of blood flow and saturation of the areas with hemangiomas were calculated using a previously developed neural network approach. The results indicate the possibility of using this system to monitor the effectiveness of hemangiomas therapy.

Keywords: hyperspectral imaging, infantile hemangiomas, neural network processing, blood volume fraction, blood oxygenation.

1. INTRODUCTION

Infantile hemangiomas are the most common vascular benign tumors in pediatrics, affecting about 5-10% of children under the age of 6 months.¹ Approximately 12% of diagnosed childhood hemangiomas require long-term therapy.² The progression of such hemangiomas is usually documented by relatively subjective methods based on physical examination, visual analog scale, and review of photographs taken.³ The measurements of the lesions made in this way and their subsequent evaluation can be inaccurate, as they depend largely on the subjective opinion of the operator (angle and lighting of the photographs, etc.). The lack of an objective tool for assessing hemangiomas makes it difficult to decide on the correct course of lesion treatment and to compare the effectiveness of different treatments. It follows that the task of finding and developing a new noninvasive method of measuring hemangioma areas is an important and actual task.

Today, a variety of noninvasive diagnostic methods for infantile hemangiomas are already used in clinical practice, allowing the evaluation of the efficacy of the treatment of this pathology, but at the same time having a range of significant limitations. For example, various radiographic methods⁴ used are associated with a high radiation load on the child and the need to perform investigations under anesthesia. The ultrasound examinations of hemangiomas used in most cases are not able to make an accurate diagnosis and are used as an additional examination.⁵ In this regard, methods of optical noninvasive diagnostics designed to measure the absorption and scattering properties of optically heterogeneous media, such as biological tissues, are promising. According to the assumption that the appearance of hemangiomas is influenced by hypoxic stress of local tissues, the analysis of oxygenation by detection of diffuse reflectance radiation can be used in the evaluation of the effectiveness of the treatment of this disease. Thus, the aim of this study was to develop a system of noninvasive diagnostics of infantile hemangiomas in order to further form an objective criterion for evaluating the efficacy of the treatment.

Send correspondence to Valery Shupletsov
E-mail: valery.shupletsov@bmcenr.ru

2. MATERIAL AND METHODS

To achieve the aim, we developed a system of optical imaging based on registration of diffuse light reflection from tissues using a hyperspectral approach. A developed halogen source with a radiation power of 60 mW and a probing area of approximately 20 cm² was used as a broadband radiation source. Specim hyperspectral camera (Specim, Spectral Imaging Ltd., Finland) with spectral range of 400–1000 nm and exposure time of 150 ms was used as a detector.

Infantile hemangiomas were studied in two children under the age of 6 months with different localization of neoplasms (in the temporal and abdominal regions). Each patient was positioned in the supine position on a medical couch. The conducted studies were approved by the Ethics Committee of Orel State University. For all experiments performed in accordance with the research methodology, registration of diffuse reflected radiation from the object of study with subsequent analysis of the obtained spectra was carried out. To normalize the data, registration of spectra from the diffuse reflectance standard was performed. The obtained results were processed using a previously developed neural network trained by a generalized object-oriented Monte Carlo model.^{6–8}

3. RESULTS AND DISCUSSION

As a result, hyperspectral image arrays of two infantile hemangiomas were obtained. Fig. 1 shows averaged normalized diffuse reflectance spectra for the tumor and intact healthy tissue areas, respectively. The revealed difference in the shape of reflection spectra indicates a change in the optical properties of hemangioma nidus compared to intact tissue, which allows further mathematical processing of the results.

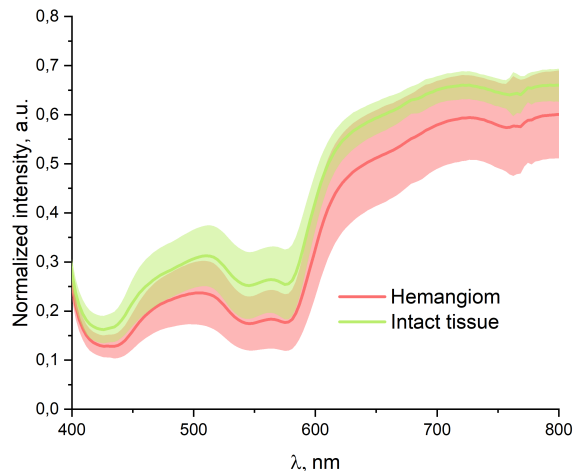


Figure 1. Averaged normalized diffuse reflectance spectra for hemangiomas and intact healthy tissue.

Using a neural network approach, based on previously obtained hyperspectral arrays of infantile hemangiomas, we calculated two-dimensional maps of blood volume fraction and blood oxygen saturation. The results shown in Fig. 2, are presented in the form of a box plot, including the averaged values of the blood volume fraction (Fig. 2a) and skin blood saturation parameters (Fig. 2b) for the tumor and intact areas of healthy tissues.

Hemangioma tissue is known to be oversaturated with blood vessels¹ and similar to the placenta, which is confirmed by the detected increase in the blood volume fraction in the hemangioma area compared to intact tissue (Fig. 2a, $p < 0.005$). It is also suggested that hemangioma growth occurs when tissues and blood vessels receive insufficient oxygen. Thus, the identified decrease in the oxygen saturation index in the hemangiomas area compared to normal values in intact tissue⁹ (Fig. 2b, $p < 0.001$) indicates the possibility of using the developed diagnostic system. However, when ulceration occurs, an increase in oxygen saturation can be observed in the area of hemangiomas associated with arterioportal shunts.¹⁰ From this we can conclude that the correct interpretation of hemangioma monitoring depends on many factors, including the stage of tumor growth.

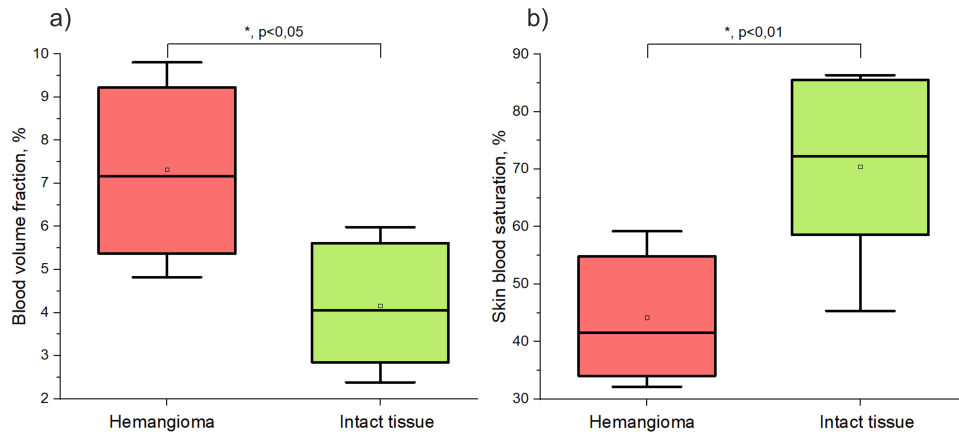


Figure 2. Estimated blood volume fraction (a) and oxygen saturation (b) for hemangiomas and intact healthy tissue.

4. CONCLUSION

Analysis of the measurement results of infantile hemangiomas demonstrated the possibility of an effective assessment of blood volume and oxygen saturation parameters using the previously developed neural network approach. The possibilities of the developed diagnostic system with the purpose of its further use for monitoring of hemangiomas treatment efficiency are demonstrated. It is important to note that there are limitations in the application of the proposed method associated with uncontrolled movements of the body of infants, which must be taken into account during measurements.

ACKNOWLEDGMENTS

The study was supported by the Russian Science Foundation under the project No. 21-15-00325.

REFERENCES

- [1] Boscolo, E. and Bischoff, J., "Vasculogenesis in infantile hemangioma," *Angiogenesis* **12**(2), 197–207 (2009).
- [2] Kilcline, C. and Frieden, I. J., "Infantile hemangiomas: how common are they? a systematic review of the medical literature," *Pediatr. Dermatol.* **25**(2), 168–173 (2008).
- [3] Torres, E. B., Wittel, J. B., van Esso Arbolave, D. L., Bosch, M. I. F., Sanz, Á. C., de Lucas Laguna, R., del Pozo Losada, J., Martín, Á. H., Montañés, L. J., Gutiérrez, J. C. L., et al., "Spanish consensus on infantile haemangioma," *Anales de Pediatría* **85**(5), 256–265 (2016).
- [4] Menapace, D., Mitkov, M., Towbin, R., and Hogeling, M., "The changing face of complicated infantile hemangioma treatment," *Pediatr. Radiol.* **46**(11), 1494–1506 (2016).
- [5] Ding, A., Gong, X., Li, J., and Xiong, P., "Role of ultrasound in diagnosis and differential diagnosis of deep infantile hemangioma and venous malformation," *J. Vasc. Surg. Venous. Lymphat. Disord.* **7**(5), 715–723 (2019).
- [6] Zhrebtsov, E., Dremin, V., Popov, A., Doronin, A., Kurakina, D., Kirillin, M., Meglinski, I., and Bykov, A., "Hyperspectral imaging of human skin aided by artificial neural networks," *Biomed. Opt. Express* **10**(7), 3545–3559 (2019).
- [7] Dremin, V., Marcinkevics, Z., Zhrebtsov, E., Popov, A., Grabovskis, A., Kronberga, H., Geldnere, K., Doronin, A., Meglinski, I., and Bykov, A., "Skin complications of diabetes mellitus revealed by polarized hyperspectral imaging and machine learning," *IEEE Trans. Med. Imaging* **40**(4), 1207–1216 (2021).
- [8] Dremin, V. V., Zhrebtsov, E. A., Popov, A. P., Meglinski, I. V., and Bykov, A. V., "Hyperspectral imaging of diabetes mellitus skin complications," *Biomedical Photonics for Diabetes Research*, 177–195 (2022).
- [9] Akons, K., Dann, E. J., and Yelin, D., "Measuring blood oxygen saturation along a capillary vessel in human," *Biomed. Opt. Express* **8**(11), 5342–5348 (2017).
- [10] Chaturvedi, A., Kliensky, N. B., and Saul, D., "Ultrasound with doppler evaluation of congenital hepatic vascular shunts," *Pediatr. Radiol.* **48**, 1658–1671 (2018).