

A Multiparametric Approach to the Assessment of Cutaneous Microcirculation in Dermatological Patients (on the Example of Patients with Psoriasis)

E. V. Potapova^{a, *}, M. A. Mikhailova^{a, b}, A. K. Koroleva^a, D. D. Stavtsev^a, V. V. Dremin^{a, c}, A. V. Dunaev^a,
N. Yu. Yakushkina^{a, d}, A. I. Krupatkin^e, and N. B. Margaryants^f

^a Orel State University, Orel, 302026 Russia

^b National Medical Research Center for Therapy and Preventive Medicine, Ministry of Health of the Russian Federation, Moscow, 101990 Russia

^c Aston University, Birmingham B4 7ET, United Kingdom

^d Orel Regional Dermatovenerological Dispensary, Orel, 302030 Russia

^e Priorov National Medical Research Center for Traumatology and Orthopedics, Ministry of Health of the Russian Federation, Moscow, 127299 Russia

^f National Research University ITMO, St. Petersburg, 197101 Russia

*e-mail: potapova_ev_ogu@mail.ru

Received October 30, 2020; revised November 22, 2020; accepted February 20, 2021

Abstract—The article describes a multiparametric approach to the assessment of cutaneous microcirculation in dermatological patients (using the example of psoriasis patients). The multiparametric diagnostic approach consisted of three stages of successive measurements performed according to the methodology of laser speckle contrast imaging (LSCI), laser Doppler flowmetry (LDF), and videocapillaroscopy (VCS). Experimental studies on hemodynamic parameters were conducted in psoriatic patients with a course of conservative treatment. A combined application of optical noninvasive diagnostic methods allowed physicians to record changes taking place in the microcirculatory bed during treatment. It has been found that microcirculatory disorders observed before the start of treatment in the field of psoriatic plaques (an increase in the density of the capillary network, an increase in the indicator of microcirculation, nutritive blood flow and the amplitudes of myogenic and cardiac oscillations) were normalized due to the applied treatment, on which the assessment of its efficacy may be based. The suggested approach may be used for diagnosing microcirculatory disorders emerging in psoriasis in its preclinical stage, as well as for developing and testing new pharmacological means for its treatment.

Keywords: noninvasive diagnostics, laser Doppler flowmetry, laser speckle contrast imaging, videocapillaroscopy, blood microcirculation, psoriasis

DOI: 10.1134/S0362119721050091

Psoriasis is a chronic recurrent inflammatory skin disease with hyperproliferation of epidermal cells, keratinization dysfunction, and inflammatory response in the derma accompanied by changes in different organs and systems. According to statistical data, this dermatosis occurs in 2–3% of the world's population [1]. The understanding of pathogenic mechanisms underlying psoriasis still remains controversial. The question remaining unanswered so far is either psoriasis is mainly an epidermal disease accompanied by dermal and vascular changes or the onset of lesions occurs in the derma and blood vessels and secondarily provokes hyperproliferation of the epidermis. However, the fact that an important and, probably, a decisive role in the pathogenesis of the disease belongs

to microvascular changes is generally recognized by the entire scientific medical community [2–4].

Microcirculatory disorders, as a characteristic symptom of psoriasis, emerge long before the appearance of the clinical picture of the disease. Histological and capillaroscopic investigations showed that the stationary stage of the disease is characterized by tortuosity of capillary loops in the papillary derma and the elongation of their venous portion [2, 5–7]. A widened capillary bed and a total increase of the number of functioning capillaries cause an enhanced blood flow in the field of psoriatic plaques, compared with the clinically uninvolved skin [8, 9]. The microvascular changes occur before or immediately at the early stage of developing lesions before epidermal hyperplasia and gradually disappear as soon as the skin returns to

the normal skin blood microcirculation in the course of treatment. The increased skin perfusion returns to normal values, capillaries with the predominance of venous portion transform into arterial capillaries resembling those typical of healthy skin [3, 6, 10]. Thus, microcirculatory changes play an important part in the pathogenesis and treatment of psoriasis and serve as a reliable diagnostic parameter.

Dermatologists are currently very limited in choosing instrumental methods for diagnosing and monitoring the dynamics in the treatment of psoriasis. The disease diagnosis is based on a subjective approach, including collecting the data on the disease history and analyzing the clinical picture, and depends on the physician's qualification and experience. It is necessary to develop the methods possessing a high informative reliability and sensitivity coupled with the possibility of having a real-time diagnosis, which could be introduced into clinical practice for objectivizing the criteria for choosing a treatment strategy and monitoring the treatment in dynamics.

Optical noninvasive diagnostic methods, such as the Laser Speckle Contrast Imaging (LSCI), Video-capillaroscopy (VCS), Laser Doppler Flowmetry (LDF), Fluorescence Spectroscopy, Diffuse Reflectance Spectroscopy, Photoplethysmography, Optical Coherence Tomography, etc., are now widely used in many disciplines of medicine [11–13], particularly, in dermatology, in diagnosing microcirculatory disorders in psoriasis, eczema and other skin diseases [14–16]. A novel area in the development of optical noninvasive diagnostics is associated with a multiparametric approach, when different research methods are combined into one diagnostic technology, which allows specialists to obtain highly effective diagnostics tools. Therefore, we suggest using an approach to allow us to analyze together the microcirculatory blood flow parameters recorded simultaneously by three instrumental methods, such as LDF, LSCI, and VCS.

The LSCI method is based on recording a random speckle picture formed by the photodetector, gathering backscattered light from the surface of the tissue and the moving blood elements (erythrocytes), illuminated with coherent laser radiation [17]. It is possible, using LSCI, to record two-dimensional blood flow maps at a very high spatio-temporal resolution [18]. The LDF method is based on testing a biological tissue by low level laser radiation and recording, using the Doppler effect, the reflected and scattered radiation from erythrocytes moving in the diagnostic volume [19]. The LDF technique allows one not only to evaluate the blood perfusion in the field being investigated, but also to analyze the state of different blood-flow regulation mechanisms, using a spectral analysis of the signal recorded. The VCS technique is based on recording and analyzing the motion of erythrocytes combined with a possibility to evaluate their velocity inside particular capillaries by video recording a series

of shots with capillary blood flow [20]. This real-time technology allows us to identify both the functional and the structural alterations in the microcirculatory dysfunction at the capillary level.

Therefore, the objective of this study was to investigate the functional state of the microcirculatory bed in the upper limbs of patients suffering from psoriasis and subsequently evaluate the efficacy of the applied conservative treatment based on a multiparametric optical approach.

METHODS

The cohort of patients was represented in the study by six patients (three women and three men) aged 36 ± 16 years from the Dermatovenerological Department) of the Orel Regional Dermatovenerological Dispensary (Orel, Russia) with the diagnosis of common psoriasis in a stationary stage. To assess the efficacy of conservative therapies, the investigations concerning the functional state of the microcirculatory bed in the patients' lower limbs were conducted on a multiparametric approach and repeated by three times, including on the day of their hospitalization and on days 6 and 12 of treatment. In total, the summary statistics of investigations was represented by 18 measurements for each of the optical diagnostic methods, LSCI, LDF, and VCS.

The study group included patients with psoriatic lesions on the inner side of the forearm. The choice of the indicated region was caused by the minimal risk for external factors to affect the given area and an easy access to the area of investigation, which allows us to obtain reliable information about the nutritive microvascular blood flow in the tissue investigated. The exclusion criteria for patients were as follows: the history of acute periods of cardiovascular and bronchopulmonary diseases, as well as the acute states of the diseases of liver, kidneys, blood factors, and veins, i.e., the conditions that could influence the final results of investigations. The main clinical laboratory indicators were measured in line with the standard laboratory protocols. Blood pressure was measured after a patient's 5-min rest in a sitting position. The main clinical laboratory indicators for subjects of a dermatological profile are shown in Table 1 (the mean values and the standard deviation ($M \pm \sigma$) are shown).

The average inpatient length of stay for patients with psoriasis at the Dermatological Department was 12–14 days. The patients were treated according to the following standard regimen, including the following medication and instrumental treatment: intravenously, sodium thiosulfate 30% (10.0 mL) and Rheopolyglukin (400.0 mL); intramuscularly, vitamin B6 (2.0 mL); subcutaneously, aloe (1.0 mL); perorally, Essentiale Forte H (300 mg 2 drops 3 times a day), Pentoxifylline (1 pill 2 times a day), Aevit (1 capsule 2 times a day), folic acid (1 tablet 2 times a day), and

Pavlov’s mixture (1 tbsp 3 times a day); externally, salicylic ointment 5%, Dermovate Merhem, and serum salicylic ointment 2 times a day; and whole-body UV phototherapy .

All measurements were taken in a room at constant air temperature ($+23 \pm 1^\circ\text{C}$) in the state of psychic and physical rest for subjects in a sitting position after 15-min adaptation to room conditions. The investigated limb was positioned horizontally at the heart level.

Figure 1 shows the measuring scheme for investigating patients with psoriasis using a multiparametric approach combining three stages of successive measurements: LSCI, LDF, and VCS.

To image blood perfusion of tissues in the investigated area by the LSCI method at the initial stage, we used an experimental installation developed on the base of the R&D Center of Biomedical Photonics (Orel State University, Orel, Russia). The experimental installation included a laser source with a power of 10 mW, working at a wavelength of 635 nm (Edmund Optics, USA), the emission of which is projected onto a patient’s skin surface, using a laser beam expander. To record speckle images, a DCC 3260M CMOS camera (1936 × 1216 pixels resolution; 5.86 μm pixel size, Thorlabs, USA) was used in combination with a MVL25M23 objective lens (focus distance, 25 mm; Thorlabs, USA). The speckle images were recorded in the investigated tissue area on the inner side of the forearm during 30 s. The frequency of frames during the video recording was 40 Hz. The resulted speckle images were transmitted to a PC for a further analysis with the application of the algorithm developed in the Matlab environment [21].

To assess the dynamic changes in blood microcirculation in the investigated area, we used a spatio-temporal algorithm for the analysis of speckle statis-

Table 1. The main clinical laboratory indicators in the investigated psoriatic patients ($M \pm \sigma$)

No.	Indicator	Value
1	Gender (M/F)	3/3
2	Age, years	36 ± 16
3	Bodyweight index, kg/m ²	25 ± 3
4	Duration of the disease, years	16 ± 13
5	SBP, mmHg	126 ± 9
6	DBP, mmHg	82 ± 7
14	The area of the affected skin, %	36 ± 14

tics, and the mean contrast was calculated by the equation

$$K = \left\langle \frac{\sigma_N}{\langle I \rangle_N} \right\rangle_k, \tag{1}$$

where $\langle \rangle$ is the symbol for averaging; N is the $N \times N$ window of averaging; k is the number of covered images; $k = 20$; $\langle I \rangle_N$ is the mean intensity in the $N \times N$ window; σ_N is the standard deviation in the $N \times N$ window; $N = 7$.

In imaging blood perfusion in the given area, the dark shades of gray correspond to low values of calculated contrast and a high velocity of scattering particles, whereas the light shades correspond to a high contrast and a low velocity.

At the second stage, hemodynamic parameters were investigated using the LDF channel of a LAKK-M analyzer (SPE “LAZMA” Ltd., Russia). In the LDF channel, a biological tissue is tested at a wavelength of 1064 nm, and the diagnostic volume, on

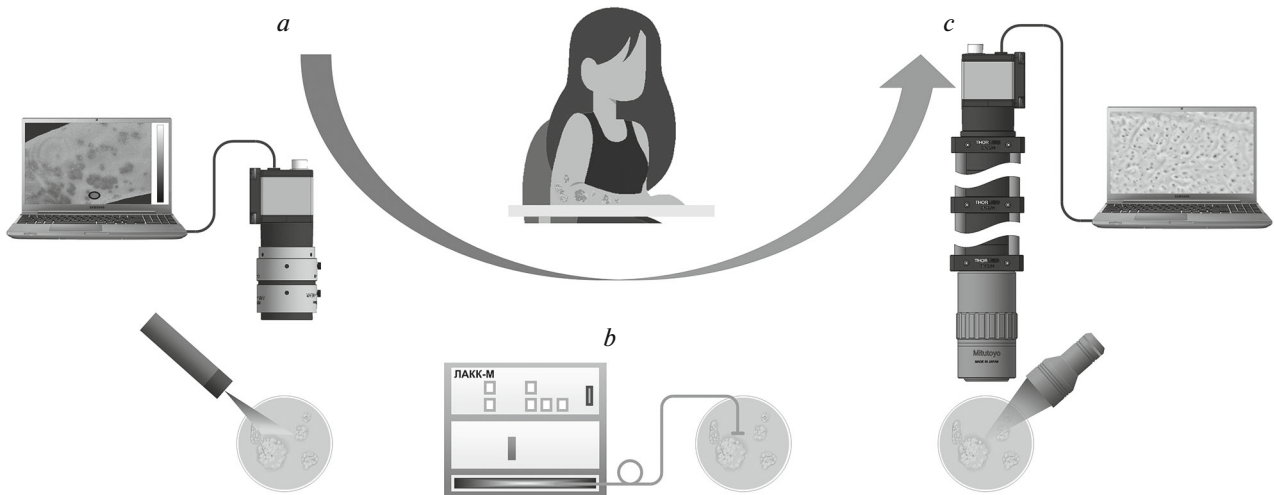


Fig. 1. Scheme of the investigation of psoriatic patients with the application of a multiparametric approach: (a) the first investigation stage using the laser speckle contrast imaging (LSCI); (b) the second investigation stage using the laser Doppler flowmetry method (LDF); (c) the third investigation stage using the videocapillaroscopy method (VCS).

average, reaches 1–3 mm³. Blood perfusion (I_m , PU) was recorded both in the area of psoriatic lesion and on the plot of uninvolved (intact) tissue, at a distance of 1–2 cm from the affected area, during 10 min in each plot. For the frequency analysis on different regulatory mechanisms, we used the LDF3.0.2.384 software (SPE “LAZMA” Ltd., Russia) employing the continuous wavelet transform, using the complex Morlet wavelet as an analyzing wavelet. The LDF signal was decomposed using the wavelet transform as follows:

$$W(s, \tau) = \frac{1}{\sqrt{s}} \int_{-\infty}^{\infty} x(t) \psi^* \left(\frac{t - \tau}{s} \right) dt,$$

where $x(t)$ is the targeted signal, τ is the position parameter corresponding to a temporal shift, s is the coefficient of scaling, $*$ is complex conjugation. The

Morlet wavelet is determined as $\psi(t) = e^{2\pi i t} e^{-t^2/\sigma}$ and used with the damping parameter $\sigma = 1$. This wavelet allows providing a sufficient frequency-temporal resolution and is well localized in a temporal area.

Amplitudes were calculated for oscillations of the endothelial (A_e , PU), neurogenic (A_n , PU), myogenic (A_m , PU), respiratory (A_r , PU) and cardiac (A_c , PU) origin [19]. To assess the contribution of different blood flow ways to the general flow using the methods based on the amplitude-frequency spectrum analysis [22], taking predominantly into account the absence of arteriolar-venular anastomoses in the skin on the inner side of the forearm, we calculated the indicator of bypass grafting characterizing the proportion of the blood flow in the arteriolar–venular anastomoses (I_{mAVA} , PU) and the nutritive blood flow value (I_{mn} , PU).

The indicator for bypass grafting was calculated as follows: $I_{mAVA} = I_{1mAVA} + I_{2mAVA}$. I_{1mAVA} was calculated as $I_{1mAVA} = A_{act}/A_m$, where A_{act} is the maximum amplitude of blood flow oscillations, which is associated with active regulatory mechanisms (the oscillations of endothelial, neurogenic, and myogenic genesis), A_m is the amplitude of blood flow oscillations in the myogenic range.

The I_{2mAVA} value was calculated as follows: $I_{2mAVA} = A_{pass}/A_m$, where A_{pass} is the maximal blood flow amplitude associated with the passive regulatory mechanisms (the oscillations of the pulsatile or respiratory origin). The I_{2mAVA} value was taken into account during the calculation of the bypass grafting indicator, if $I_{2mAVA} \geq 1$. The nutritive blood flow was calculated by the following equation: $I_{mn} = I_m/I_{mAVA}$.

At the third stage, the VCS method was used to determine the number of imaged capillaries in the psoriatic plaque and the intact tissue, as well as for the analysis of the structural organization of capillaries. The installation used for conducting the investigations

was developed on the base of the R&D Center of Biomedical Photonics (Orel State University, Orel, Russia), the optical system of which consisted of a Mitutoyo M Plan APO 5× micro-objective lens (Thorlabs, Inc., USA) with an aperture of 0.14, projecting the image of capillaries through a long-focus lens (200 mm focus distance) on the camera matrix. The data were recorded using a high-speed CMOS UI-3060-C-HQ camera (IDS, Germany). In the course of the investigation, a recording was continued for 1 min with the image resolution of 800 × 800 pixels and the image frequency of 150 Hz in the area of psoriatic lesion and on the plot of uninvolved (intact) tissue at a distance of 1–2 cm from the affected area. The 1-min recording allowed us at the data processing stage to choose the analyzed images with the best quality. To obtain a better contrast, the area of investigation was illuminated by a lateral light with a light-emitting diode source with a wavelength of 560 nm, corresponding to the isobestic point of the oxy- and deoxy-hemoglobin absorption spectra. The experimental device was assembled with a moving stand, and its vertical regulation provided the focusing of the optical system on the investigated area. The images obtained by the VCS method were analyzed using the following methods. The following tasks were performed: the density of the capillary network was determined by calculating the number of functioning capillaries per 1 mm² of tissue, and the morphology of the functioning capillaries and their form were evaluated.

The experimental data were analyzed statistically. The significance of statistical differences between the samples was assessed using the Mann–Whitney test, $p < 0.05$. Part of statistical analysis results is represented as span diagrams, where the central line is the median, the box frames are the lower and upper quartiles.

RESULTS AND DISCUSSION

The LSCI investigation method and the developed software allowed us to record the image of the skin blood flow in patients with psoriasis through calculating the spatiotemporal contrast obtained for twenty successive images in dynamic speckle patterns. Figure 2 shows an example for a change in the spatial distribution of local contrast assessments in one of the patients recorded on days 1, 6 and 12 after inpatient admission.

When patients with psoriasis were investigated using LSCI, a patched pattern was observed at different therapeutic stages, due to interchanged zones with enhanced and normal microcirculation. The zones with a decreased contrast level corresponded to the places of location of psoriatic plaques. A large number of psoriatic lesions were recorded in patients on the first admission day, and this was confirmed also by the LSCI data. On day 6 of the treatment, the area of lesions and their number began to decrease. On treat-

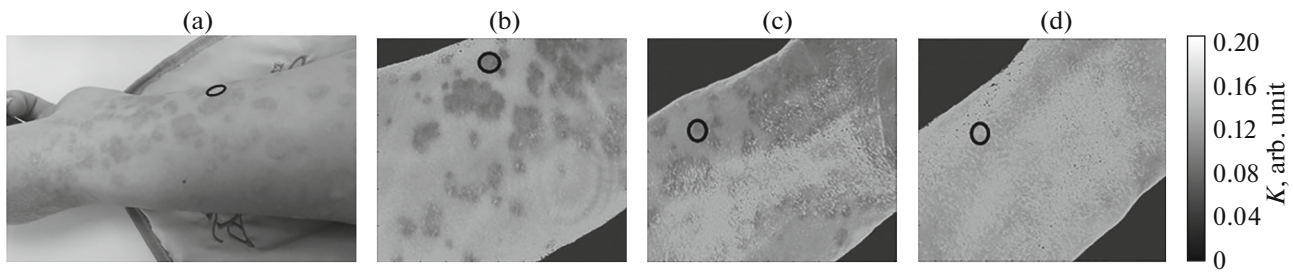


Fig. 2. Speckle-contrast images obtained during the investigation of the skin blood flow in patients with psoriasis at different stages of treatment. The isolated fields correspond to the field of recording the LDF signals in a plaque. (a) A photograph of the field of investigation (the inner surface of the forearm); (b) investigation results obtained by the laser speckle-contrast imaging method (LSCI) on day 1 of inpatient admission; (c) on treatment day 6; (d) on treatment day 12.

ment day 12, imaging of the skin blood flow in the forearm showed that the total contrast and the contrast of an isolated field increased, and fields of low contrast values were practically unobserved.

The area on the inner side of the forearm for which the LDF signals in a plaque were subsequently recorded in a given patient was expressed. The LDF signals were additionally recorded on the plot of uninvolved tissue. Figure 3 presents the statistical treatment results on the data obtained by the LDF method at different stages of the treatment as diagrams of the span and the statistically significant values are indicated for the parameters.

At the third stage, we used the VCS method and obtained video images of capillaries in a psoriatic plaque and the intact tissue. The example of the VCS results in one of the patients obtained on days 1, 6, and 12 after the admission is shown in Fig. 4.

Figure 5 shows the calculation results obtained by the VCS method on the density of capillaries in a psoriatic lesion and an intact area, and statistically significant differences are indicated between the parameters recorded at different treatment stages of treatment.

The results of investigation obtained by the LDF and VCS methods were additionally shown in Table 2. This has been done for suitability in the analysis on differences between the main hemodynamic parameters measured in a psoriatic plaque and in an intact area at each stage of the treatment.

Analyzing the data obtained by the LDF and VCS methods (Table 2) for the area of psoriatic lesion and uninvolved skin of the forearm, we can note that a typical pattern of microcirculatory disorders in psoriasis was observed at the first investigation stage, as described earlier [8–10, 23–27]. The VCS recorded an increase in the density of the capillary network, and capillaries in a psoriatic plaque were broadened, twisted, and lengthened, compared with an intact tissue. Statistically significant increases in the microcirculation indicator, nutritive blood flow, and amplitudes of oscillations associated with cardiac contrac-

Table 2. Calculation results for the main hemodynamic indicators ($M \pm \sigma$)

Indicator	Stage 1		Stage 2		Stage 3	
	psoriatic plaque	intact tissue	psoriatic plaque	intact tissue	psoriasis plaque	intact tissue
Investigation results according to the LDF method						
I_m , PU	12.1 ± 1.8*	7.2 ± 2.6	12.5 ± 2.4	9.8 ± 3.3	6.9 ± 1.7	5.8 ± 3.3
I_{mn} , PU	4.4 ± 1.5*	2.5 ± 0.6	3.9 ± 1.6	2.8 ± 1.3	1.8 ± 0.6	2.1 ± 1.6
I_{mAVA} , PU	2.7 ± 1.2	3.1 ± 1.2	3.6 ± 1.1	3.9 ± 1.2	4.3 ± 1.7	3.5 ± 1.9
$A(e)$, PU	0.4 ± 0.1	0.3 ± 0.1	0.3 ± 0.1	0.3 ± 0.1	0.2 ± 0.1	0.2 ± 0.1
$A(n)$, PU	0.4 ± 0.2	0.3 ± 0.1	0.3 ± 0.1	0.3 ± 0.1	0.2 ± 0.1	0.2 ± 0.1
$A(m)$, PU	0.6 ± 0.3*	0.2 ± 0.1	0.3 ± 0.2	0.3 ± 0.2	0.2 ± 0.1	0.2 ± 0.1
$A(r)$, PU	0.4 ± 0.2	0.2 ± 0.03	0.3 ± 0.04	0.2 ± 0.07	0.3 ± 0.3	0.1 ± 0.06
$A(c)$, PU	0.8 ± 0.1*	0.4 ± 0.1	0.7 ± 0.2	0.6 ± 0.1	0.5 ± 0.2	0.3 ± 0.1
Investigation results according to the VCS method						
Density of capillaries	59 ± 4	48 ± 10	58 ± 3*	42 ± 5	52 ± 3*	42 ± 5

LDF, laser Doppler flowmetry; VCS, videocapillaroscopy; * statistically significant differences between the indicators measured in a psoriatic plaque respective to an intact field with probability $p < 0.05$.

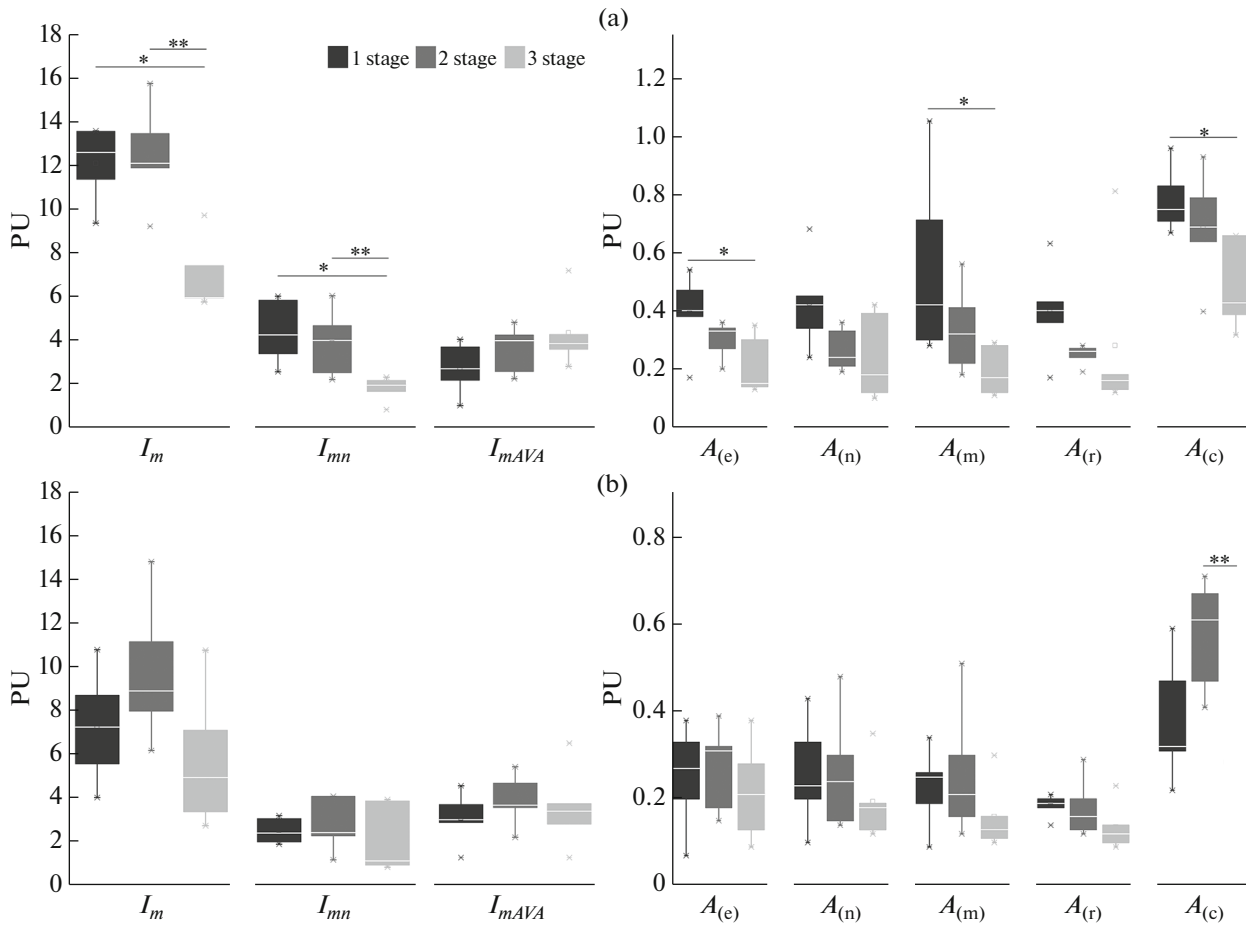


Fig. 3. Calculated parameters of blood microcirculation by the investigation results obtained by the laser Doppler flowmetry method (LDF): (a) psoriatic plaque, (b) intact field. * Statistically significant differences from the first investigation stage at $p < 0.05$; ** statistically significant differences from the second investigation stage at $p < 0.05$.




Fig. 4. VCS recordings of capillaries in psoriatic lesions of one of patients at different treatment stages. A: (a) VCS investigation results on day 1 of inpatient admission; (b) on treatment day 6; (c) on treatment day 12. I, a psoriatic plaque; II, an intact field.

tions were observed in the recorded LDF signal. High indicators for the amplitudes of myogenic oscillations in psoriatic lesions pointing at the enhanced vasomotions associated with the internal activity of smooth muscle cells could correspond to an increase in the blood flow in the arterial component of the microcirculatory bed of psoriatic plaques and inclusion of compensatory mechanisms. This is explained by the fact that hemodynamics in the microcirculatory bed, and, especially, in its capillary component is determined not only by the internal forces of circulation, but also by metabolic requirements of the tissues surrounding the capillaries. A growth in the level of metabolism in the focus of psoriatic inflammation causes, due to active angiogenesis, an enhanced blood inflow to the capillary bed.

The investigated hemodynamic parameters were normalized against the administration of conservative treatment (Figs. 3–5). At the final stage, a statistically significant decrease was observed in the mean number of imaged superficial capillary loops in the psoriatic lesion. An analogous picture was also observed in an intact tissue, but no statistically significant differences have been identified here. There was also a decrease in the values of the indicators for blood microcirculation, nutritive blood flow and an increase in the value of bypass grafting indicator in a psoriatic plaque, which points at the blood flow redistribution towards the grafting constituent and a reduction in the capillary perfusion and can indirectly confirm a decrease in the inflammatory process as a result of a correctly selected treatment course. A statistically significant decrease in psoriatic lesion was also recorded at the final investigation stage in the amplitudes of endothelial, myogenic, and cardiac contractions. Predominance of endothelial rhythms along with myogenic and cardiac ones is a sign of microcirculatory disorders in psoriasis [25], and, hence, the statistically significant decrease in the complex of the indicated oscillation in dynamics of psoriasis treatment may also confirm a positive effect of the applied medication and instrumental treatment. The intact tissue was observed to show a decreasing trend in blood perfusion and amplitudes of all blood flow oscillations by the third stage of the study, but this has remained unconfirmed statistically.

We should note that the specificity of the microcirculation indicator dynamics, which was diagnosed at the second stage of the study, requires a more detailed study in future. On treatment day 6, the indicator for blood microcirculation in the intact tissue showed a decreasing trend, as compared with the pretreatment indicators, which was, most probably and predominantly, associated with the effect of cardiac oscillations. This may have been caused by the response by patients' bodies to the applied local treatment, as well as by the metabolic processes in the tissues surrounding the capillaries, which needs more deepened study with the application of functional tests.

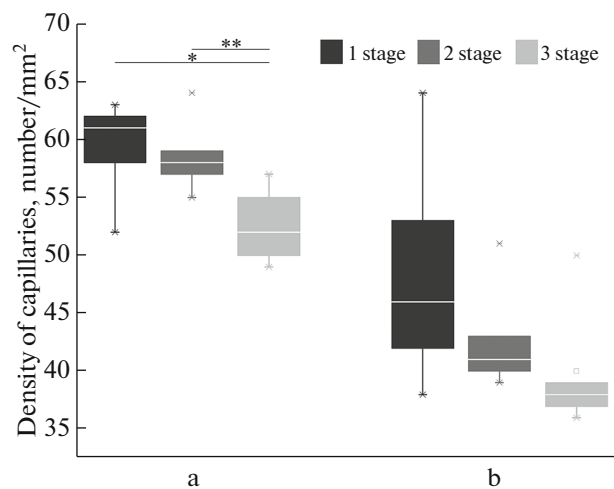


Fig. 5. Calculated results for the density of capillaries by the results obtained by videocapillaroscopy (VCS): (a) psoriatic plaque; (b) intact field. * Statistically significant differences from the first stage of the investigation at $p < 0.05$; ** statistically significant differences from the second investigation stage at $p < 0.05$.

A positive dynamic in the main microhemodynamic blood parameters was observed in the course of treatment in all the participants of the study to a greater or smaller degree, which also agreed with improvements in the condition of skin surfaces and other clinical manifestations of this disease (such as itching and scaling).

The use of the LSCI, LDF, and VCS methods individually or in combination may have an important clinical application for diagnosing microcirculatory disorders in patients with psoriasis. The LSCI method has sufficiently good prospects for its application in dermatology. For example, the summary statistics excluded the case with one female patient in whom the fields of enhanced blood circulation measured by the LDF method where blood perfusion also demonstrated the growth trend was identified at the second stage of investigations against the absence of obvious signs of worsening. Based on this information, the dermatologist corrected the treatment; however, this female patient did not continue her investigation with optic diagnostic methods, due to personal reasons. It has been found when analyzing the obtained data that some part of the recorded LSCI shots (including the shot of the given patient's hand on the second day of the investigation) had non-uniform image illumination, and therefore, the investigation methods require further research before its introduction into the clinical practice. The analysis of a combination of the data on LDF signals and VCS images during our investigations allowed us to diagnose microcirculatory disorders in both patients with a long-term history of the disease and patients with a disease history not exceeding 1.5 years. Furthermore, it has been confirmed that

the suggested integrated approach to the diagnosis of microcirculatory disorders allowed us to assess the efficacy of the recommended medication and instrumental therapies in psoriatic patients and the results of our investigations confirm the aforementioned suggestions.

CONCLUSIONS

Microcirculatory changes in psoriasis are one of the leading factors in the pathogenesis of this disease. Previous studies have allowed us to suggest that vascular changes in the skin emerge long before the clinical manifestations of the disease. Psoriasis is a systemic disease with characteristic concomitant changes in the affected skin portions, and, most probably, initial skin lesions emerge from the derma and blood vessels, and this secondarily provokes hyperproliferation of the epidermis. The treatment aiming at improving the state of general microcirculation and reduce inflammation helps to normalize the state of the microcirculatory and tissue systems, which is confirmed by a positive dynamic in a patient's total condition, as well as hemodynamic parameters in psoriatic lesions.

Our investigation data confirm a high diagnostic potential of the offered integrated approach to the identification of microcirculatory disorders in psoriatic patients. The LSCI, LDF, and VCS methods give us the possibility of analysing the spatial distribution of perfusion, identify the areas with disorders in microcirculation and study mechanisms underlying these disorders using the study of blood flow regulation in microvessels, assessment of the nutritive blood flow and the specificities in the distribution of capillaries in the lesion and the intact area at different disease treatment stages.

Before conservative treatment for psoriatic lesions, an increase in the density of the capillary network and perfusion in a psoriatic plaque, compared with the intact tissue was identified in patients with psoriasis, and dominance of myogenic and cardiac oscillations and an increase in the nutritive blood flow were recorded in these areas. The described changes in microcirculatory hemodynamics of psoriatic plaques were caused by active inflammatory processes therein. As a result of the treatment, the microcirculation was normalized in the foci of skin lesions and a statistically decrease was observed in the indicated hemodynamic parameters measured in a plaque.

The introduction of this approach into a dermatological clinical practice may allow not only the applied conservative treatment to be evaluated in terms of efficacy, but also the medication and instrumental treatment to be timely corrected, diseases to be diagnosed at early stages (even before the clinical manifestations of initial symptoms), and the emergence of complications (including psoriatic arthritis) to be prevented, which will substantially increase the efficacy of the

applied treatment, reduce the financial and temporal treatment expenses, and, as a result, improve the quality of life.

FUNDING

The study was supported by the Russian Foundation for Basic Research (RFBR), project no. 19-32-50007. V.V. Dremin kindly acknowledges personal support from the European Union's Horizon 2020 research and innovation program under the Marie Skłodowska-Curie grant agreement No. 839888.

COMPLIANCE WITH ETHICAL STANDARDS

All investigations were performed in the correspondence with the principles of biomedical ethics stipulated under the 1964 Helsinki Declaration and its subsequent revisions and approved by the local bioethics committee of Orel State University, Orel, Russia (protocol no. 10 of November 16, 2018).

INFORMED CONSENT

Each participant in this study gave his/her voluntary written informed consent signed by him/her after informing him/her about potential risks and advantages, as well as about the nature of the forthcoming study.

CONFLICT OF INTEREST

The authors declare the absence of obvious and potential conflicts of interest associated with the publication of this article.

REFERENCES

1. Eberle, F.C., Brück, J., Holstein, J., et al., Recent advances in understanding psoriasis, *F1000 Research*, 2016, vol. 5, p. 770.
2. Micali, G., Lacarrubba, F., Musumeci, M.L., et al., Cutaneous vascular patterns in psoriasis, *Int. J. Dermatol.*, 2010, vol. 49, no. 3, p. 249.
3. Heidenreich, R., Röcken, M., and Ghoreschi, K., Angiogenesis drives psoriasis pathogenesis, *Int. J. Exp. Pathol.*, 2009, vol. 90, no. 3, p. 232.
4. Zraggen, S., Ochsenbein, A.M., and Detmar, M., An important role of blood and lymphatic vessels in inflammation and allergy, *J. Allergy*, 2013, vol., 2013, p. 672381.
5. De Angelis, R., Bugatti, L., Del Medico, P., et al., Videocapillaroscopic findings in the microcirculation of the psoriatic plaque, *Dermatology*, 2002, vol. 204, no. 3, p. 236.
6. Braverman, I.M. and Sibley, J., Role of the microcirculation in the treatment and pathogenesis of psoriasis, *J. Invest. Dermatol.*, 1982, vol. 78, no. 1, p. 12.
7. Golińska, J., Sar-Pomian, M., and Rudnicka, L., Dermoscopic features of psoriasis of the skin, scalp and

- nails—a systematic review, *J. Eur. Acad. Dermatol. Venereol.*, 2019, vol. 33, no. 4, p. 648.
8. Hern, S., Stanton, A.W.B., Mellor, R.H., et al., Blood flow in psoriatic plaques before and after selective treatment of the superficial capillaries, *Br. J. Dermatol.*, 2005, vol. 152, no. 1, p. 60.
 9. Potapova, E.V., Filina, M.A., Kozlov, I.O., et al., Specific local blood microcirculation in patients with psoriasis, *Reg. Krovoobrashch. Mikrotsirkulyatsiya*, 2018, vol. 17, no. 3, p. 58.
 10. Hern, S. and Mortimer, P.S., In vivo quantification of microvessels in clinically uninvolved psoriatic skin and in normal skin, *Br. J. Dermatol.*, 2007, vol. 156, no. 6, p. 1224.
 11. Zherebtsova, A.I., Dremin, V.V., Makovik, I.N., et al., Multimodal optical diagnostics of the microhaemodynamics in upper and lower limbs, *Front. Physiol.*, 2019, vol. 10, p. 416.
 12. Yun, S.H. and Kwok, S.J.J., Light in diagnosis, therapy and surgery, *Nat. Biomed. Eng.*, 2017, vol. 1, no. 1, art. ID 0008.
 13. Tuchin, V.V., *Handbook of Optical Biomedical Diagnostics*, Vol. 2: *Methods*, Bellingham, WA: SPIE, 2016.
 14. Tkaczyk, E., Innovations and developments in dermatologic non-invasive optical imaging and potential clinical applications, *Acta Derm. Venereol.*, 2017, suppl. 218, p. 5.
 15. Grajdeanu, I.-A., Statescu, L., Vata, D., et al., Imaging techniques in the diagnosis and monitoring of psoriasis, *Exp. Ther. Med.*, 2019, vol. 18, no. 6, p. 4974.
 16. Lacarrubba, F., Pellacani, G., Gurgone, S., et al., Advances in non-invasive techniques as aids to the diagnosis and monitoring of therapeutic response in plaque psoriasis: a review, *Int. J. Dermatol.*, 2015, vol. 54, no. 6, p. 626.
 17. Briers, J.D., Laser Doppler, speckle and related techniques for blood perfusion mapping and imaging, *Physiol. Meas.*, 2001, vol. 22, no. 4, p. R35.
 18. Boas, D.A. and Dunn, A.K., Laser speckle contrast imaging in biomedical optics, *J. Biomed. Opt.*, 2010, vol. 15, no. 1, p. 011109.
 19. Krupatkin, A.I. and Sidorov, V.V., *Funktsional'naya diagnostika sostoyaniya mikrotsirkulyatorno-tkanevykh sistem: kolebaniya, informatsiya, nelineinost'. Rukovodstvo dlya vrachei* (Functional Diagnostics of Microcirculatory Tissue Systems: Fluctuations, Information, and Nonlinearity: A Manual for Physicians), Moscow: URSS Editorial, 2016.
 20. Dremin, V.V., Kozlov, I.O., Volkov, M.V., et al., Dynamic evaluation of blood flow microcirculation by combined use of the laser Doppler flowmetry and high-speed videocapillaroscopy methods, *J. Biophoton.*, 2019, vol. 12, no. 6, p. e201800317.
 21. Potapova, E.V., Seryogina, E.S., Dremin, V.V., et al., Laser speckle contrast imaging of blood microcirculation in pancreatic tissues during laparoscopic interventions, *Quant. Electron.*, 2020, vol. 50, no. 1, p. 33.
 22. Dunaev, A.V., Sidorov, V.V., Krupatkin, A.I., et al., Investigating tissue respiration and skin microhaemocirculation under adaptive changes and the synchronization of blood flow and oxygen saturation rhythms, *Physiol. Meas.*, 2014, vol. 35, no. 4, p. 607.
 23. Rosina, P., Zamperetti, M.R., Giovannini, A., and Girolomoni, G., Videocapillaroscopy in the differential diagnosis between psoriasis and seborrheic dermatitis of the scalp, *Dermatology*, 2007, vol. 214, no. 1, p. 21.
 24. Rosina, P., Giovannini, A., Gisondi, P., and Girolomoni, G., Microcirculatory modifications of psoriatic lesions during topical therapy, *Skin Res. Technol.*, 2009, vol. 15, no. 2, p. 135.
 25. Adyrkhaeva, D.A., Natarova, E.V., and Ryumkina, N.A., Specific indicators of laser Doppler flowmetry in psoriasis, *Vestn. Nov. Med. Tekhnol.*, 2007, vol. 14, no. 1, p. 120.
 26. Hendriks, A.G.M., Steenbergen, W., Hondebrink, E., et al., Whole field laser Doppler imaging of the microcirculation in psoriasis and clinically unaffected skin, *J. Dermatol. Treat.*, 2014, vol. 25, no. 1, p. 18.
 27. Dremin, V.V., Filina, M.A., Zharkikh, E.V., et al., Peculiarities of local blood microcirculation in patients with psoriasis, *Proc. SPIE*, 2018, vol. 10685.

Translated by N. Tarasyuk